



Case Report

Acute subdural hematoma associated with disruption of tumor vessels due to rapid growth of falx meningioma: A case report and literature review

Kohei Oyamada, Hidenori Ohbuchi, Kae Nishiyama, Daisuke Imazato, Mayuko Inazuka, Shinji Hagiwara, Yuichi Kubota

Department of Neurosurgery, Tokyo Women's Medical University Adachi Medical Center, Tokyo, Japan.

E-mail: Kohei Oyamada - verdasco.ko.2@gmail.com; *Hidenori Ohbuchi - hide.ohbuchi@gmail.com; Kae Nishiyama - kaenishi.6@gmail.com; Daisuke Imazato - imadai_mentanpin@yahoo.co.jp; Mayuko Inazuka - apprivoiser.ferrox@gmail.com; Shinji Hagiwara - hagiwara.shinji@twmu.ac.jp; Yuichi Kubota - kubota.yuichi@twmu.ac.jp



*Corresponding author:

Hidenori Ohbuchi,
Department of Neurosurgery,
Tokyo Women's Medical
University Adachi Medical
Center, Tokyo, Japan.

hide.ohbuchi@gmail.com

Received : 17 June 2022

Accepted : 06 October 2022

Published : 28 October 2022

DOI

10.25259/SNI_553_2022

Quick Response Code:



ABSTRACT

Background: Meningiomas associated with acute subdural hematoma (ASDH) are rare. The rapid growth of meningiomas has been shown to be one of the mechanisms underlying bleeding. We report the first case of ASDH during an imaging follow-up for the rapid growth of a falx meningioma.

Case Description: A 77-year-old woman was diagnosed with an incidental tumor along the right falx cerebri 3 years before bleeding. The follow-up magnetic resonance imaging (MRI) after 3 years showed that the tumor volume had rapidly increased from 4.31 cm³ to 22.27 cm³. The blood vessels around the tumor were stretched. The patient was scheduled to undergo tumor removal surgery. However, the patient experienced a sudden onset of disturbance of consciousness and was transferred to our hospital. On arrival, her Glasgow Coma Scale (GCS) score was 6 (E1V1M4) and right hemiplegia was observed. The patient had no history of traumatic events. Computed tomography (CT) showed left hemispheric and interhemispheric ASDH. Digital subtraction angiography revealed neither tumor staining nor abnormal vessels. Gross total tumor removal and hematoma evacuation were performed. There were no obvious active intraoperative bleeding points. The pathologic diagnosis was meningioma, the World Health Organization Grade I. Postoperative course revealed a GCS score of 10 (E4V1M5) and she was transferred to a rehabilitation hospital.

Conclusion: The disruption of tumor vessels due to the rapid growth of meningiomas may be a cause of bleeding. Incidental falx meningiomas with stretched tumor vessels due to rapid growth could indicate the need for early surgery.

Keywords: Acute subdural hematoma, Falx meningioma, Hemorrhage, Meningioma, Rapid growth

INTRODUCTION

Meningiomas are benign tumors and the most common central nervous system tumors in adults.^[5] Meningiomas presenting with spontaneous hemorrhage are rare, occurring only in approximately 2% of cases.^[8] Moreover, rapid growth of incidental meningioma confirmed before bleeding is uncommon.^[1,10] Only eight cases of falx meningioma with acute subdural hematoma (ASDH) have been reported.^[4,6,9,12,13,17,18] This is the first case report of ASDH with rapid growth of a falx meningioma found during imaging follow-up.

This is an open-access article distributed under the terms of the Creative Commons Attribution-Non Commercial-Share Alike 4.0 License, which allows others to remix, transform, and build upon the work non-commercially, as long as the author is credited and the new creations are licensed under the identical terms.

©2022 Published by Scientific Scholar on behalf of Surgical Neurology International

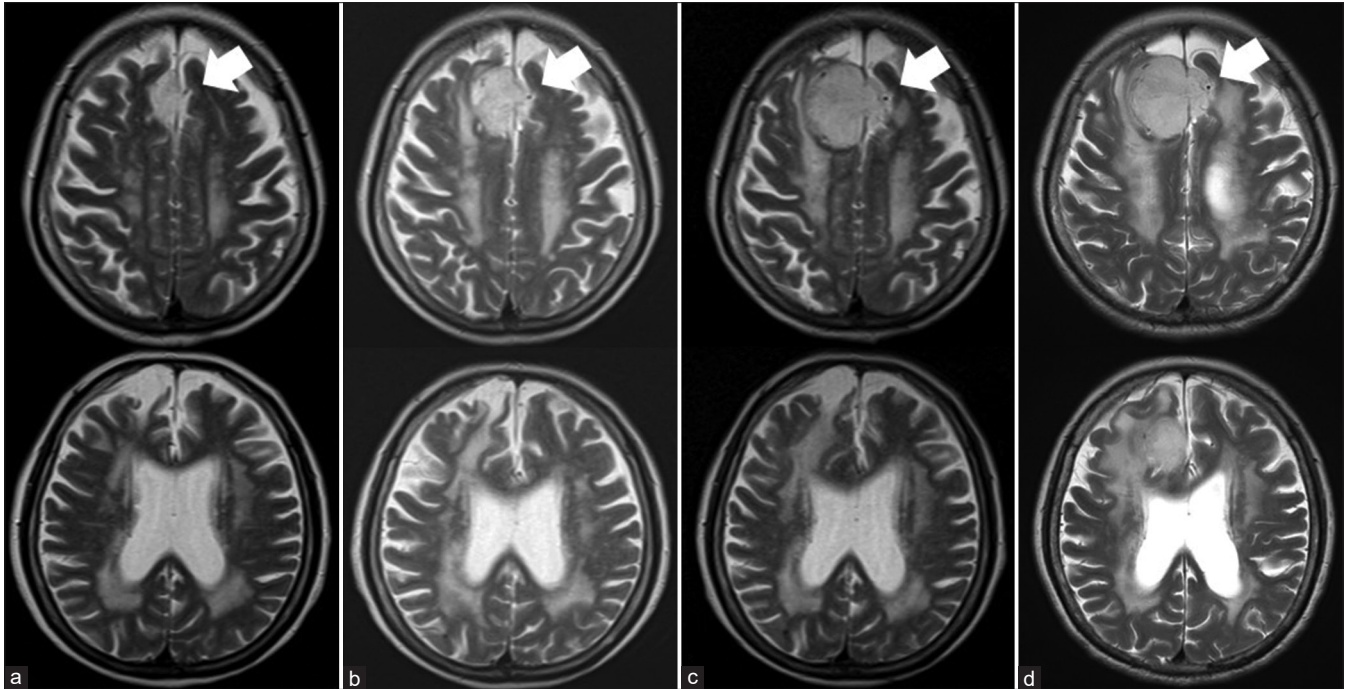


Figure 1: Follow-up MRI scans; white arrows indicate flow voids on the left side of the tumor corresponding to adjacent vessels: (a) initial MRI images obtained 3 years before bleeding. Tumor volume: 4.31 cm³, (b) second follow-up MRI images obtained 1 year before bleeding. Tumor volume: 12.76 cm³, (c) third follow-up MRI images obtained 2 months before bleeding. Adjacent blood vessels were stretched and moved to the left due to rapid tumor growth. Tumor volume: 21.67 cm³, and (d) fourth follow-up MRI images obtained 2 weeks before bleeding. Tumor volume: 22.27 cm³.

CASE DESCRIPTION

A 77-year-old woman with a history of cerebral infarction and chronic low back pain was taking antiplatelet drugs and selective serotonin reuptake inhibitors (SSRI). She had undergone magnetic resonance imaging (MRI) at another hospital 3 years before bleeding because of a headache, and an incidental tumor (volume 4.31 cm³) along the right falx cerebri had been identified. MRI showed the tumor as a well-circumscribed, slightly high-intensity area on T2-weighted images and a dural tail sign. The tumor was suspected to be a falx meningioma. The follow-up MRI 1 year before bleeding showed that the tumor had rapidly grown to 12.76 cm³. The follow-up MRI 2 weeks before bleeding showed 22.27 cm³ of volume and grown not only to the right but also to the left falx cerebri. Furthermore, MRI revealed a left flow void showing blood vessels that had moved from the median side to the lateral side due to tumor growth [Figure 1]. She was scheduled for tumor removal as MRI showed a rapidly growing tumor. However, she experienced a sudden onset of disturbance of consciousness and was transferred to our hospital before scheduled treatment. On arrival, her Glasgow Coma Scale (GCS) was 6 (E1V1M4) and the right hemiplegia was observed. She had no history of traumatic events or physical scarring. After admission, the patient presented with generalized convulsions and was administered anti-

seizure medication. Computed tomography (CT) revealed left hemispheric ASDH, interhemispheric ASDH, and intracerebral hematoma extending from the left intra-/extra-tumoral lesion. Contrast CT showed extravasation in the hematoma of the left frontal lobe. Digital subtraction angiography (DSA) performed 1 day after admission showed neither tumor staining nor abnormal vessels. In the venous phase of the bilateral common carotid angiogram, the anterior part of the superior sagittal sinus (SSS) revealed no obliteration [Figure 2].

Tumor removal and hematoma evacuation were performed 3 days after admission. First, we removed the left frontal hematoma due to an increase in dural pressure and subsequently confirmed a decrease in dural pressure. Second, we performed internal decompression of the tumor and incised the SSS and falx to block feeding arteries. Third, we dissected the tumor from the surrounding normal brain parenchyma, removed the gross total of the tumor together with the falx of the attachment (Simpson Grade I), and drained the hematoma. No clear active bleeding points or intratumoral subacute clot was found intraoperatively. Fragile and irregular vessels were attached to the tumor wall.

The pathological diagnosis was confirmed as meningotheial meningioma (the World Health Organization [WHO] Grade I according to the 2016 Classification of Tumors of

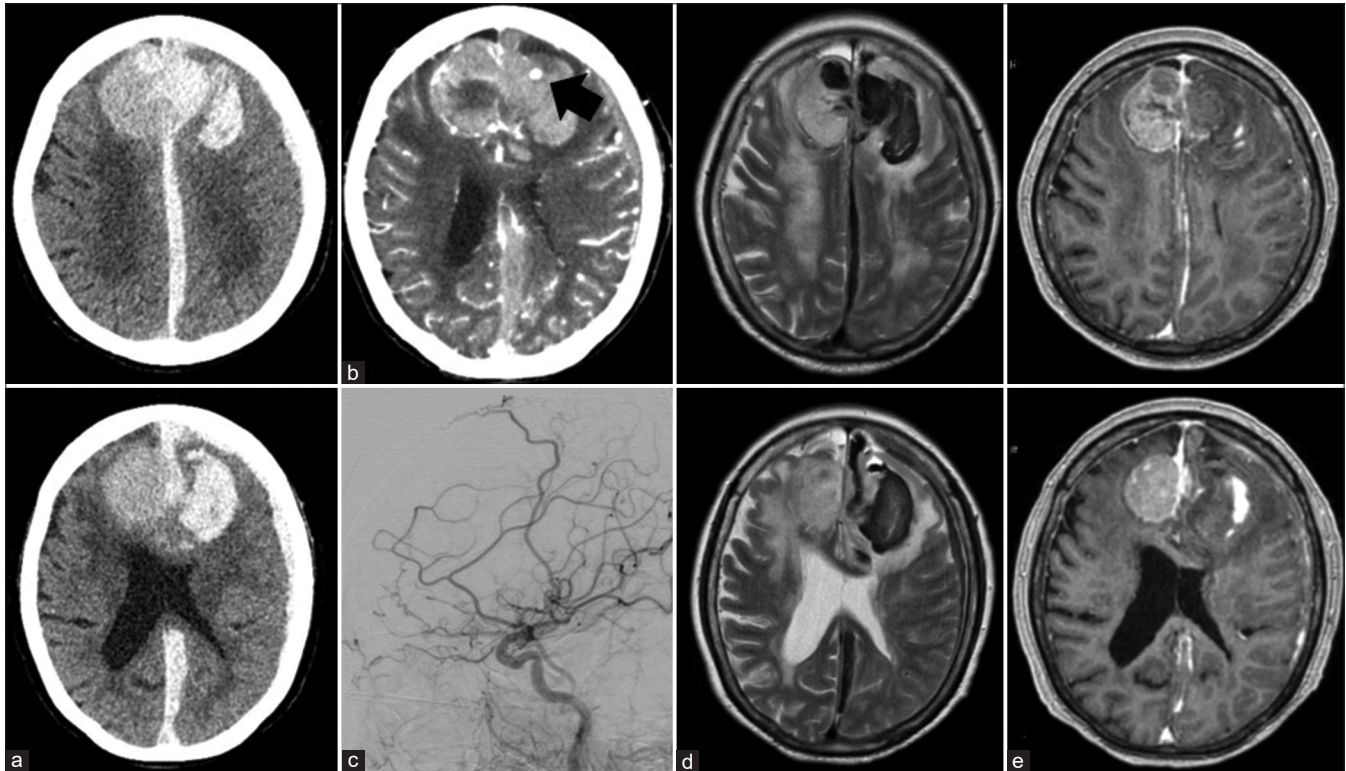


Figure 2: Imaging at onset of bleeding: (a) the head CT images at onset of bleeding showed left acute subdural hematoma (ASDH), interhemispheric ASDH, and intracerebral hematoma extending from the left intra-/extra-tumoral lesion. (b) Enhanced CT showing extravasation (black arrow) in the hematoma of the left frontal lobe. (c) Left lateral DSA of the left CCA revealed neither tumor staining nor abnormal vessels. (d and e) The mass lesion on the MRI image shows a mixed signal intensity area on T2-weighted images.

the Central Nervous System^[11]). Postoperative CT confirmed the removal of the tumor and hematoma. Postoperative enhanced MRI revealed gross total tumor removal [Figure 3]. Her GCS score was 10 (E4V1M5) and she was transferred to a rehabilitation hospital.

DISCUSSION

Meningiomas accompanied by subdural hematoma are uncommon.^[14] Among them, falx meningioma is exceedingly rare; to date, only eight cases, including this case, have been reported [Table 1].^[4,6,9,12,13,14,17,18] Among the reported cases, six involved female patients (75%) and the mean age was 68 years (range, 61–78 years). Most cases of bleeding occur when the tumor is first identified, and only in this case, the tumor was identified before bleeding. Most of the symptoms at the time of bleeding were headaches, and the degree and symptoms of the bleeding at that time varied from mild to severe; however, most cases were mild. The pathological WHO grade was I in all cases and meningiomas were not malignant. The all cases were 2016 revised system classification.

In five of the eight cases, the cause was bleeding due to suspected disruption of the tumor vessels, but this case was

the only one showing rapid growth in imaging follow-up. The patient's prognosis was generally good. However, when massive bleeding was observed at the time of admission, as in this case, the prognosis could be poor.

Several hypotheses have been proposed as the mechanism for the rapid growth of meningiomas accompanied by massive ASDH: (1) disruption of fragile tumor vessels by rapid growth of tumors; this mechanism was most commonly reported,^[6,12,14,18] (2) disruption of bridging veins by rapid tumor growth,^[2,6,14,16] (3) direct invasion of blood vessels by tumor cells,^[6,14,16] (4) vasoactive substances released by tumor cells,^[6,14] (5) disruption of bridging veins by local venous hypertension caused by a secondary condition (e.g., Valsalva maneuver and cough),^[14,17] and (6) anticoagulant or antiplatelet medications, blood dyscrasias, or hypertension.^[6,14,15]

Previously, rapid growth was reported to occur in 16–25% of meningiomas.^[1,10] In the present case report, the tumor volume was 4.31 cm³ 3 years before bleeding, 12.76 cm³ 1 year before bleeding, 21.67 cm³ 2 months before bleeding, and 22.27 cm³ 2 weeks before bleeding, showing a rapid growing tumor (defined as growth > 2 cm³/yr^[11]). In fact, this tumor is the most rapidly growing falx meningioma reported to date.^[7] All tumor volumes were measured on an imaging series by

Table 1: Reported cases of hemorrhagic falx meningioma accompanied by acute subdural hematoma.

Case number	Author (year)	Age (years)	Sex	Manifesting symptoms	Imaging follow-up before bleeding	Clinical presentations at the time of bleeding	Side of bleeding	Type of hematoma	Meningioma WHO grade*	Suspected cause of bleeding	Outcome
1	Okuno <i>et al.</i> , 1999 ^[13]	78	F	Hemorrhage	No	Vomiting and disorder of consciousness	Right	ASDH	I	Vessel rupture caused by vascular stress	Mild disability
2	Goyal <i>et al.</i> , 2003 ^[6]	66	F	Hemorrhage	No	Headache	Left	ASDH	I	Rupture of the abnormal tumor vessel	Good recovery
3	Dallocchio <i>et al.</i> , 2003 ^[4]	73	F	Hemorrhage	No	Left hemiparesis and disorder of consciousness	Right	ICH/ASDH	Not known	Not known	Mild disability
4	Krishnan <i>et al.</i> , 2015 ^[9]	62	M	Hemorrhage	No	Headache and right hemiparesis	Left	ICH/ASDH	I	Not known	Good recovery
5	Suzuki <i>et al.</i> , 2018 ^[8]	61	F	Hemorrhage	No	Headache and right hemiparesis	Bilateral	ASDH	I	Rupture of the abnormal tumor vessel	Good recovery
6	Matsuoka <i>et al.</i> , 2019 ^[12]	61	F	Hemorrhage	No	Headache	Left	ASDH	I	Rupture of the fragile tumor vessel	Good recovery
7	Sato <i>et al.</i> , 2019 ^[7]	68	M	Hemorrhage	No	Headache	Right	ICH/ASDH	I	Venous hypertension	Good recovery
8	Present case, 2022	77	F	Incidental	Yes	Right hemiparesis and disorder of consciousness	Left	ICH/ASDH	I	Vessel stretching and rupture	Severe disability

F: Female, M: Male, ASDH: Acute subdural hematoma, ICH: Intracerebral hemorrhage, WHO: World Health Organization, WHO Grade*: The criteria for classification and grading according to the 2016 Classification of Tumors of the Central Nervous System

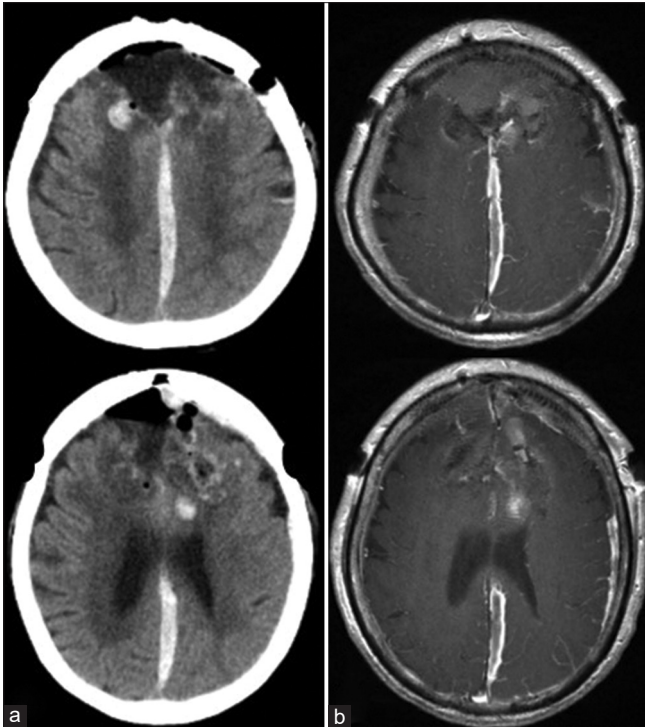


Figure 3: Postoperative imaging: (a) postoperative head CT images showing removal of the tumor and hematoma. (b) Enhanced MRI images showing gross total removal.

the same author to minimize interuser variability using the inherent tools of the Picture Archiving and Communication System (Fujifilm, Tokyo, Japan) technology. Tumor volumes were obtained through manual and/or semiautomatic segmentation with systematic review and correction using the Livewire correction tool for every slice.^[7]

In this case, the tumor was not a pathologically malignant meningioma and had no apparent traumatic mechanism. Intraoperative findings revealed stretched fragility and irregularity of the vessels in the tumor wall. Moreover, from a retrospective point of view, the follow-up image before bleeding confirmed that the blood vessels around the tumor had stretched due to the rapid growth of the tumor. On the contralateral bleeding side, the tumor rapidly grew and was large but not bleeding. It was considered that there were no stretched fragile vessels around the tumor. Contrast CT immediately after bleeding showed extravasation at the same site as the stretching blood vessels. No obvious vascular abnormalities were observed on angiography. In this case, during the rapid growth of the tumor confirmed by imaging follow-up, disruption of the stretched blood vessels led to bleeding, which is consistent with previous assumptions.

Recent studies showed that the risk factors for hemorrhage from meningioma were age, location, malignant histopathology, presence of hypertension, anticoagulant

or antiplatelet use, and Serotonin Noradrenaline Reuptake Inhibitor (SNRI) use.^[3,8,15] This patient was also an older adult, had hypertension, and was prescribed antiplatelet and SNRI drugs. It was assumed that the risk of bleeding was originally high, which may have caused massive bleeding.

CONCLUSION

We report the first case of ASDH due a falx meningioma that showed rapid growth during imaging follow-up. This was speculated to be caused by the disruption of stretched tumor vessel due to the rapid growth of the falx meningioma. Patients at high risk of bleeding are prone to massive hematomas and might have a poor prognosis. Incidental falx meningiomas with stretched tumor vessels due to rapid growth suggest that early surgery may be beneficial.

Declaration of patient consent

Patient's consent not required as patient's identity is not disclosed or compromised.

Financial support and sponsorship

Nil.

Conflicts of interest

There are no conflicts of interest.

Grant support

None. The authors have no personal or institutional financial interests in drugs, materials, or devices described in this paper.

REFERENCES

1. Abi Jaoude S, Peyre M, Degos V, Goutagny S, Parfait B, Kalamarides M. Validation of a scoring system to evaluate the risk of rapid growth of intracranial meningiomas in neurofibromatosis Type 2 patients. *J Neurosurg* 2021;134:1377-85.
2. Arbelaez A, Castillo M, Armao D. Meningioma presenting as an acute subdural hematoma. *Emerg Radiol* 1999;6:149-52.
3. Bosnjak R, Derham C, Popović M, Ravnik J. Spontaneous intracranial meningioma bleeding: Clinicopathological features and outcome. *J Neurosurg* 2005;103:473-84.
4. Dallochio C, Borutti G, Frascaroli G, Camana C, Magrotti E. A sudden bleeding meningioma. *Neurol Sci* 2003;23:327-28.
5. Fathi AR, Roelcke U. Meningioma. *Curr Neurol Neurosci Rep* 2013;13:337.
6. Goyal A, Singh AK, Kumar S, Gupta V, Singh D. Subdural hemorrhage associated with falcine meningioma. *Neurol India* 2003;51:419-21.
7. Hashiba T, Hashimoto N, Izumoto S, Suzuki T, Kagawa N,

- Maruno M, *et al.* Serial volumetric assessment of the natural history and growth pattern of incidentally discovered meningiomas. *J Neurosurg* 2009;110:675-84.
8. Huang R, Su S, Yang Z, Wang H, Hong L, Chen L, *et al.* Neuroradiologic findings and clinical features of meningiomas with spontaneous hemorrhage onset: A single center 10-year experience. *World Neurosurg* 2022;162:e605-15.
 9. Krishnan P, Jena M, Kartikueyan R. Occult falcine meningioma unmasked following nearly complete hemorrhagic transformation with resultant spontaneous acute interhemispheric subdural hematoma. *J Neurosci Rural Pract* 2015;6:91-3.
 10. Lee EJ, Kim JH, Park ES, Kim YH, Lee JK, Hong SH, *et al.* A novel weighted scoring system for estimating the risk of rapid growth in untreated intracranial meningiomas. *J Neurosurg* 2017;127:971-80.
 11. Louis DN, Perry A, Reifenberger G, von Deimling A, Figarella-Branger D, Cavenee WK, *et al.* The 2016 world health organization classification of tumors of the central nervous system: A summary. *Acta Neuropathol* 2016;131:803-20.
 12. Matsuoka G, Eguchi S, Ryu B, Tominaga T, Ishikawa T, Yamaguchi K, *et al.* Treatment strategy for recurrent hemorrhage from meningioma: Case report and literature review. *World Neurosurg* 2019;124:75-80.
 13. Okuno S, Touho H, Ohnishi H, Karasawa J. Falx meningioma presenting as acute subdural hematoma: Case report. *Surg Neurol* 1999;52:180-4.
 14. Omar AT 2nd., Starreveld YP. Meningioma associated with subdural hematoma: A systematic review of clinical features and outcomes. *World Neurosurg* 2022;158:e465-75.
 15. Pressman E, Penn D, Patel NJ. Intracranial hemorrhage from meningioma: 2 novel risk factors. *World Neurosurg* 2020;135:217-21.
 16. Russell NA, Al-Fayez N, Joaquin AJ. Acute subdural hematoma with intracranial meningioma. *Ann Saudi Med* 1993;13:369-71.
 17. Sato K, Matsuo A, Hiu T, Kurohama H, Miura S, Ito K, *et al.* Falx meningioma presenting with intratumoral hemorrhage and interhemispheric acute subdural hematoma: A case of report. *No Shinkei Geka* 2020;48:413-22.
 18. Suzuki Y, Fujimoto M, Kawakita F, Asakura F, Murata H, Morooka Y, *et al.* Tiny falx meningioma causing massive interhemispheric subdural hematoma: A case report. *NMC Case Rep J* 2018;5:51-5.

How to cite this article: Oyamada K, Ohbuchi H, Nishiyama K, Imazato D, Inazuka M, Hagiwara S, *et al.* Acute subdural hematoma associated with disruption of tumor vessels due to rapid growth of falx meningioma: A case report and literature review. *Surg Neurol Int* 2022;13:495.

Disclaimer

The views and opinions expressed in this article are those of the authors and do not necessarily reflect the official policy or position of the Journal or its management. The information contained in this article should not be considered to be medical advice; patients should consult their own physicians for advice as to their specific medical needs.